

## Hidrokoloidna obloga za kvalitetno previjanje rana sa slabom i umerenom eksudacijom



### Veličine:

187 639	10×10 cm	10 kom.
187 632	15×15 cm	10 kom.
187 631	15×20 cm	10 kom.
187 662	20×20 cm	5 kom.
187 644	20×30 cm	5 kom.

References: 1. Arnold TE, Stanley JC, Fellows EP, et al. Prospective, multicenter study of managing lower extremity venous ulcers. *Ann Vasc Surg.* 1994;8:356-362. 2. Burgess B. An investigation of hydrocolloids: a comparative prospective randomised trial of the performance of three hydrocolloid dressings. *Prof Nurse.* 1993;8(suppl 7):2-6. 3. Blitz H, Kiessling M, Kreysel HW. Comparison of hydrocolloid dressing and saline gauze in the treatment of skin graft donor sites. In: Ryan TJ, ed. *An Environment for Healing: The Role of Occlusion.* London, England: The Royal Society of Medicine; 1985:125-128. 4. Cherry GW, Ryan T, McGibbon D. Trial of a new dressing in venous leg ulcers. *The Practitioner.* 1984;228:1175-1178. 5. Day A, Dombrowski B, Farkas C, et al. Managing sacral pressure ulcers with hydrocolloid dressings: Results of a controlled, clinical study. *Ostomy / Wound Management.* 1995;41:52-65. 6. Demetriades D, Psaras G. Occlusive versus semi-open dressings in the management of skin graft donor sites. *S Afr J Surg.* 1992;30: 40-41. 7. Foyatier J. Skin grafts: healing of donor sites. *Proceedings: Going into the 90's. The Pharmacist and Wound Care, Jersey.* 1992;103-106. 8. Friedman S, Su WPD. Management of leg ulcers with hydrocolloid occlusive dressing. *Arch Dermatol.* 1984; 120:1329-1336. 9. Greguric S, Budimic D, Soldo-Belic A, et al. Hydrocolloid dressing versus a conventional dressing using magnesium sulphate paste in the management of venous leg ulcers. *Acta Dermatovenerol Croat.* 1994;2:65-71. 10. Heffernan A, Martin AJ. A comparison of a modified form of Granuflex® (Granuflex® Extra Thin) and a conventional dressing in the management of lacerations, abrasions, and minor operation wounds in an accident and emergency department. *J Accident Emerg Med.* 1994;11:227-230. 11. Madden MR, Nolan E, Finkelstein JL, et al. Comparison of an occlusive and a semi-occlusive dressing and the effect of the wound exudates upon keratinocyte proliferation. *J Trauma.* 1989;29:924-931. 12. Miburn PB, Singer JZ, Milburn MA. Treatment of scleroderma skin ulcers with a hydrocolloid membrane. *J Academy Dermatol.* 1989;21:200-204. 13. Nemeth AJ, Eaglstein WH, Taylor JR, Peerson LJ, Falanga V. Faster healing and less pain in skin biopsy sites treated with an occlusive dressing. *Arch Dermatol.* 1991;127:1679-1683. 14. Rohrich RJ, Pittman CE. A clinical comparison of DuoDERM CGF and op-site donor site dressings. *Wounds.* 1991;3:221-226. 15. Wyatt D, Mc Gowen DN, Najarian MP. Comparison of a hydrocolloid dressing and silver sulfadiazine cream in the outpatient management of second-degree burns. *J Trauma.* 1990; 30:857-865. 16. Cordts PR, Hanrahan LM, Rodriguez AA, Woodson J, LaMorte WV, Menzoian JO. A prospective, randomized trial of Unna's boot versus DuoDERM®/CGF® hydroactive dressing plus compression in the management of venous leg ulcers. *J Vasc Surg.* 1992;15:480-486. 17. Reig A, Tejerina C, Codina J, Hidalgo J, Mirabet V. Application of a new cicatrization dressing in treating second-degree burns and donor sites. *Ann MBC.* 1991;4:174-176. 18. Alvarez OM, Mertz PM, Eaglstein WH. The effect of occlusive dressings on collagen synthesis in re-epithelialization in superficial wounds. *J Surg Res.* 1983; 35:142-148. 19. Perrot J, Carsin H, Gilbaud J. Use of DuoDERM® dressing in the healing of graft donor sites in burned patients. *Ann Chir Plast Esthet.* 1986; 31:279-282. 20. Romanelli M. Objective measurement of venous ulcer debridement and granulation with a skin color reflectance analyzer. *Wounds.* 1997;9:122-126. 21. Van Rijswijk L. Full-thickness pressure ulcers: Patient and wound healing characteristics. *Decubitus.* 1993;6:16-21. 22. Seaman S, Herbster S, Muglia J, Murray M, Rick C. Simplifying modern wound management for non-professional caregivers. *Ostomy / Wound Management.* 2000; 46:18-27. 23. Jensen JL, Seeley J, Vivit S. A 40 patient randomised clinical trial to compare the performance of Allevyn Adhesive hydrocellular dressing and a hydrocolloid dressing in the management of pressure ulcers. *WOCN Proceedings.* June 1997. 24. Harding K, Cutting K, Price P. The cost-effectiveness of wound management protocols of care. *Br J Nurs.* 2000;9:S6-S24. 25. Bowler PG, Delargy H, Prince D, Fondberg L. The viral barrier properties of some occlusive dressings and their role in infection control. *Wounds.* 1993;5:1-8. 26. Hutchinson JJ, McGuckin M. Occlusive dressings: A microbiological and clinical review. *Am J Infect Control.* 1990;18:257-268. 27. Lawrence JC. Reducing the spread of bacteria. *J Wound Care.* 1993;2:48-52. 28. Mertz PM, Marshall DA, Eaglstein WH. Occlusive wound dressings to prevent bacterial invasion and wound infection. *J Am Acad Dermatol.* 1985;12:662-668. 29. Wilson P, Burroughs D, Dunn L. Methicillin resistant *Staphylococcus aureus* and hydrocolloid dressings. *Pharm J.* 1988;243:787-788. 30. Varghese MC, Balin AK, Carter DM, Caldwell D. Local environment of chronic wounds under synthetic dressings. *Arch Dermatol.* 1986;122:52-57. 31. Hutchinson JJ. A prospective clinical trial of wound dressings to investigate the rate of infection under occlusion. In: *Proceedings, Advances in Wound Management Harrogate, England/Macmillan.* 1994:93-96. 32. Lydon MJ, Hutchinson JJ, Rippon M, et al. Dissolution of wound coagulum and promotion of granulation tissue under DuoDERM®. *Wounds.* 1989;1:95:106. ©2004 ER Squibb & Sons LLC. (Code)

„Pre upotrebe detaljno proučiti uputstvo! O indikacijama, riziku upotrebe i neželjenim dejstvima na medicinsko sredstvo posavetujte se sa lekarom ili farmaceutom.“

Besplatna telefonska linija  0800 101 102 radnim danima od 8:30 – 15:30

Detaljnije informacije možete dobiti na web adresi: [www.ttmedik.co.rs](http://www.ttmedik.co.rs)



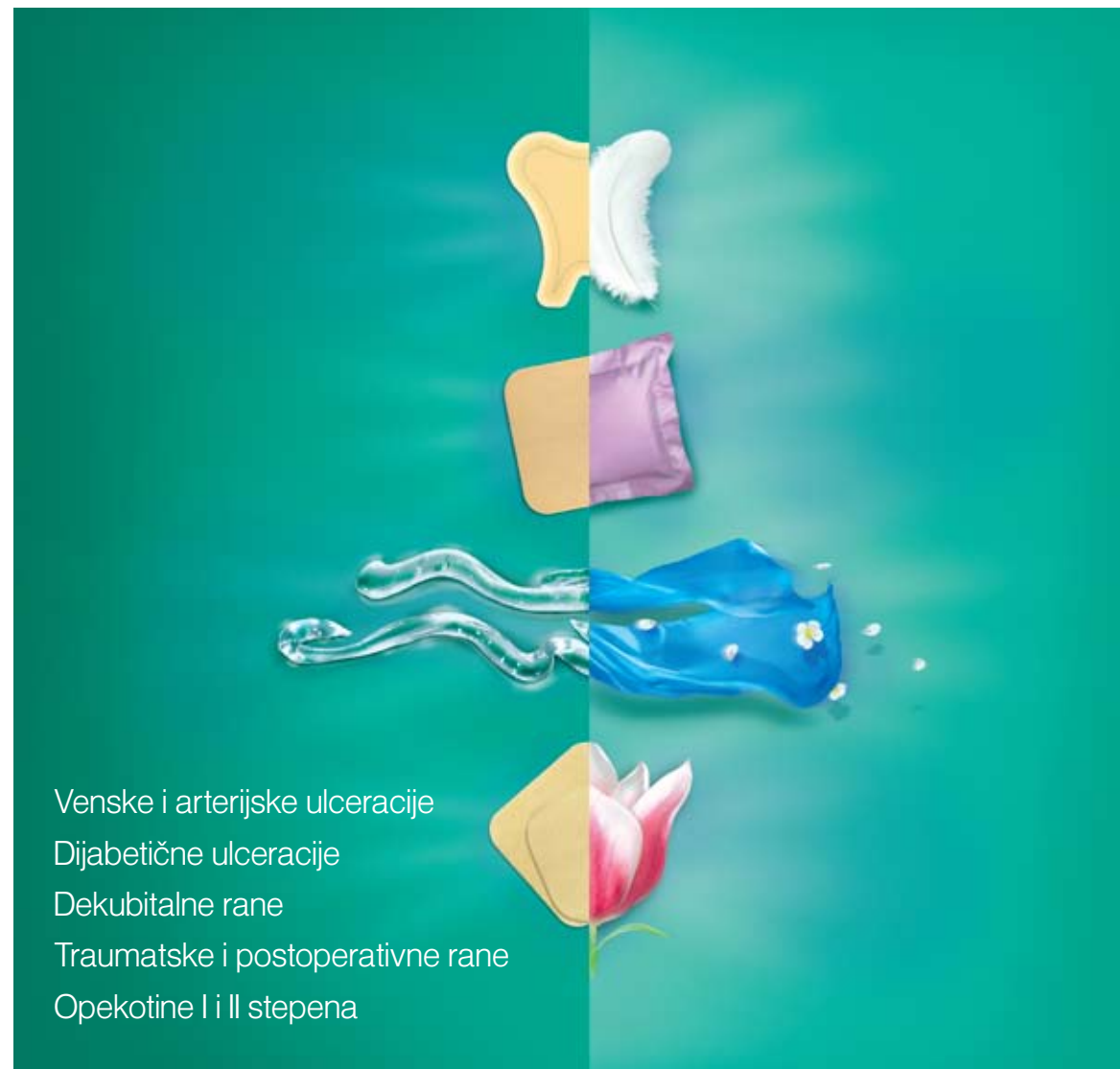ConvaTec

Realize the possibilities™



TT Medik, distributer za ConvaTec  
Bulevar Mihajla Pupina 10D/1  
11070 Novi Beograd, Srbija  
Tel: 011 311 51 52, 311 51 53  
office@ttmedik.co.rs  
www.ttmedik.co.rs

## Hidrokoloidna obloga za kvalitetno previjanje rana sa slabom i umerenom eksudacijom



Venske i arterijske ulceracije

Dijabetične ulceracije

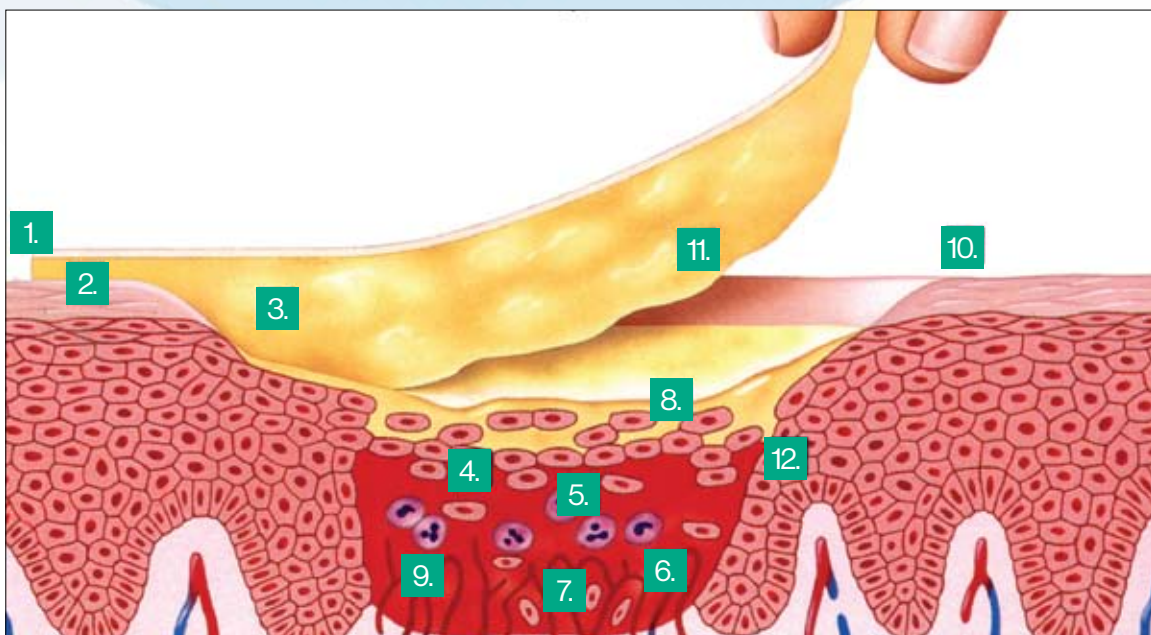
Dekubitalne rane

Traumatske i postoperativne rane

Opekotine I i II stepena

# Granuflex® hidrokoloidna obloga obezbeđuje stvaranje vlažne sredine na rani

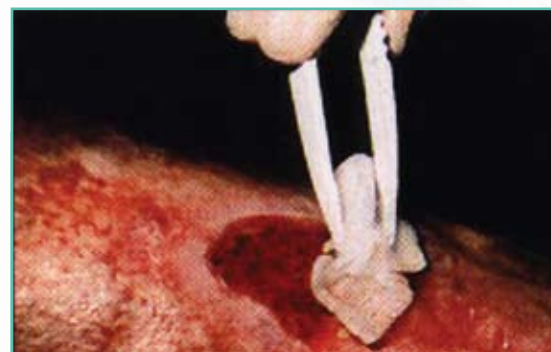## NAČIN DELOVANJA



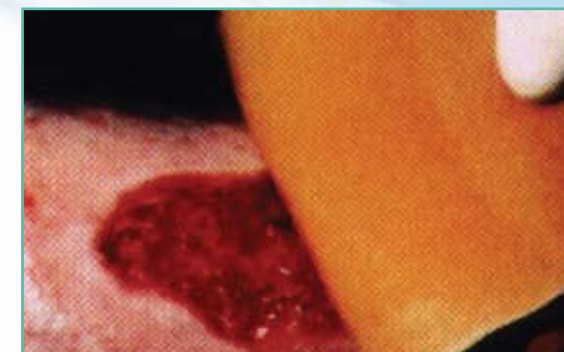- 1 Spoljni, vodootporni sloj obloge je nepropusan za vodu, gotovo nepropusan za kiseonik, i štiti ranu od urina i fecesa. Obloga je nepropusna za bakterije i viruse uključujući i MRSA, HBV i HIV – 1.<sup>25-31\*</sup>  
\* Kada je intaktna i kada nema curenja ispod obloge. Primena obloge nije garancija da neće doći do prenošenja HIV ili HBV virusa.
- 2 Interakcija sa vlagom iz kože omogućava dobro prilepljivanje obloge i formiranje zaštitnog omotača.<sup>4,5,8-12,16-18</sup>
- 3 Hidrokoloidne čestice apsorbiraju eksudat iz rane stvarajući na taj način mek, vlažan gel za koji je klinički dokazano da povoljno deluje na proces zaceljivanja rane.<sup>1-15</sup>
- 4 Toplotna izolacija koju stvara Granuflex® obloga održava temperaturu rane sličnu telesnoj.
- 5 Blago kisela sredina ispod Granuflex® hidrokoloidne obloge pomaže autolitički debridman.<sup>20,21</sup>
- 6 Pojačana je i aktivnost leukocita i njihovo fagocitno delovanje.
- 7 Hipoksična sredina pod Granuflex® oblogom pospešuje angiogenezu i stvaranje mladog granulacijskog tkiva.<sup>4,8,32</sup>
- 8 Vlažna i blago kisela sredina (pH=6,1) ubrzava proliferaciju i migraciju epidermalnih ćelija.
- 9 Bol je ublažen zahvaljujući tome što su nervni završeci stalno izloženi vlažnoj sredini.
- 10 Zamena Granuflex® obloge je bezbolna i prilikom zamene se ne oštećuje okolna koža.
- 11 Granuflex® obloga se ne lepi čvrsto za površinu rane i prouzrokuje minimalno oštećenje tkiva prilikom zamene.<sup>2-4,8,9,18,19</sup>
- 12 Sredina pod Granuflex® oblogom pojačava fibrinolitičku aktivnost, što omogućava spontano odstranjivanje naslaga.

# Vlažna sredina obezbeđuje optimalne uslove za zarastanje rana

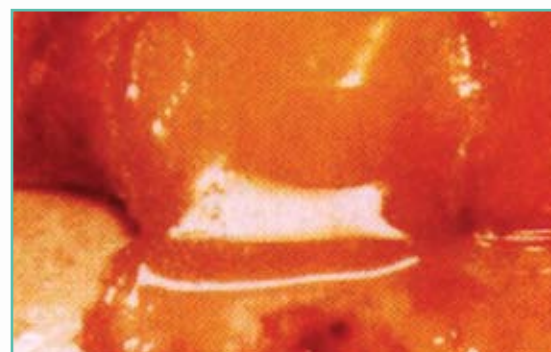## NAČIN UPOTREBE



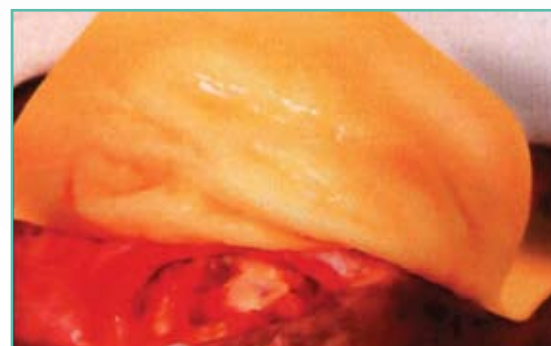1. Ranu dobro isprati fiziološkim rastvorom, a ivice rane posušiti.



2. Izabrati oblogu koja prelazi ivice rane za 2 cm. Oblogu zagrejati među dlanovima i postaviti na ranu. Blago pritisnuti rukom.



3 - 4. Hidrokoloidi obloge u kontaktu sa eksudatom iz rane formiraju gel koji se manifestuje u vidu mehura na oblozi.



5. Oblogu zameniti pre nego što gel dođe do same ivice. Ranu isprati i zatim prilepiti drugu oblogu.

Maksimalno preporučeno vreme primene jedne obloge je do sedam dana, a prosečno vreme je četiri dana.

Ukoliko je prisutna anaerobna infekcija ne preporučuje se primena okluzivne terapije

Kolonizacija hroničnih rana je česta i nije kontraindikacija za primenu obloge.